



Contents lists available at ScienceDirect

## Arab Journal of Gastroenterology

journal homepage: [www.elsevier.com/locate/ajg](http://www.elsevier.com/locate/ajg)

## Original article

## Establishing ultrasound based transient elastography cutoffs for different stages of hepatic fibrosis and cirrhosis in Egyptian chronic hepatitis C patients

Aisha Elsharkawy<sup>a,\*</sup>, Mohamed Alborai<sup>b</sup>, Rabab Fouad<sup>a</sup>, Noha Asem<sup>c</sup>, Mahmoud Abdo<sup>a</sup>, Hesham Elmakhzangy<sup>a</sup>, Mai Mehrez<sup>d</sup>, Hany Khattab<sup>e</sup>, Gamal Esmat<sup>a</sup>

<sup>a</sup> Department of Endemic Medicine and Hepatogastroenterology, Cairo University, Cairo, Egypt

<sup>b</sup> Department of Internal Medicine, Al-Azhar University, Cairo, Egypt

<sup>c</sup> Department of Public Health and Community Medicine, Cairo University, Cairo, Egypt

<sup>d</sup> National Hepatology and Tropical Medicine Research Institute, Cairo, Egypt

<sup>e</sup> Department of Pathology, Cairo University, Cairo, Egypt

## ARTICLE INFO

## Article history:

Received 18 April 2017

Accepted 12 November 2017

Available online xxx

## Keywords:

Chronic hepatitis C  
Transient elastography  
Fibrosis  
Cirrhosis  
METAVIR

## ABSTRACT

**Background and study aim:** Transient elastography is widely used to assess fibrosis stage in chronic hepatitis C (CHC). We aimed to establish and validate different transient elastography cut-off values for significant fibrosis and cirrhosis in CHC genotype 4 patients.

**Patients and Methods:** The data of 100 treatment-naïve CHC patients (training set) and 652 patients (validation set) were analysed. The patients were subjected to routine pretreatment laboratory investigations, liver biopsy and histopathological staging of hepatic fibrosis according to the METAVIR scoring system. Transient elastography was performed before and in the same week as liver biopsy using FibroScan (Echosens, Paris, France). Transient elastography results were correlated to different stages of hepatic fibrosis in both the training and validation sets.

**Results:** ROC curves were constructed. In the training set, the best transient elastography cut-off values for significant hepatic fibrosis ( $\geq$ F2 METAVIR), advanced hepatic fibrosis ( $\geq$ F3 METAVIR) and cirrhosis (F4 METAVIR) were 7.1, 9 and 12.2 kPa, with sensitivities of 87%, 87.5% and 90.9% and specificities of 100%, 99.9% and 99.9%, respectively. The application of these cut-offs in the validation set showed sensitivities of 85.5%, 82.8% and 92% and specificities of 86%, 89.4% and 99.01% for significant hepatic fibrosis, advanced hepatic fibrosis and cirrhosis, respectively.

**Conclusion:** Transient elastography performs well for significant hepatic fibrosis, advanced hepatic fibrosis and cirrhosis, with validated cut-offs of 7.1, 9 and 12.2 kPa, respectively, in genotype 4 CHC patients.

© 2017 Pan-Arab Association of Gastroenterology. Published by Elsevier B.V. All rights reserved.

## Introduction

Chronic hepatitis C (CHC) is a global health problem affecting more than 150 million people around the world. Egypt has the highest prevalence of CHC among its population. Genotype 4 is the most frequently diagnosed genotype among Egyptians. The diagnosis of CHC and its consequences is essential in determining the treatment and follow-up of Egyptian patients with CHC. Different methods for assessing hepatic fibrosis and cirrhosis (serum biomarkers, transient elastography and others) that decrease the

need for liver biopsies are currently used in clinical practice [1]. Transient elastography is one of the most frequently used methods for non-invasive assessments of hepatic fibrosis and cirrhosis worldwide [2]. The principle of transient elastography depends on the measurement of tissue elasticity using controlled generation of a shear wave via a servo-controlled vibration of known frequency and amplitude [3]. Since the first publication regarding transient elastography in 2003 [4], extensive research has been conducted, mainly in Europe, to verify the concept of its use and to validate its cut-off values in different types of chronic liver diseases [5]. In April 2013, the food and drug administration approved its use in chronic liver diseases, and its use has been subsequently expanded to the United States [6]. The cut-off values vary according to the underlying liver disease [7–9]. Moreover, the cut-off

\* Corresponding author at: Faculty of Medicine, Cairo University, Cairo 11562, Egypt.

E-mail address: [a\\_m\\_sharkawy@kasralainy.edu.eg](mailto:a_m_sharkawy@kasralainy.edu.eg) (A. Elsharkawy).

values for the same disease vary among different populations [10]. Both serum fibrosis biomarkers (APRI, FIB-4, FORNS and Egy-Score) [11–13] and transient elastography [14] show good correlations with hepatic fibrosis and cirrhosis stages in Egyptian CHC patients. Using locally validated cut-off values may improve the diagnostic accuracy of transient elastography for the assessment of different stages of hepatic fibrosis and cirrhosis in CHC. In this study, we aimed to establish and validate different cut-off values for significant hepatic fibrosis, advanced hepatic fibrosis and cirrhosis in Egyptian CHC patients and to compare the diagnostic accuracy of transient elastography with that of frequently used serum markers of hepatic fibrosis.

## Patients and methods

The retrospective data of 100 treatment-naïve CHC patients as a training set and of 652 treatment-naïve CHC patients as a validation set were analysed. Patients were collected from different CHC treatment centres in Egypt. Patients were identified as having CHC if they had positive hepatitis C virus antibody and positive hepatitis C virus ribonucleic acid (HCV-RNA) results by polymerase chain reaction (PCR) for more than 6 months. Patients with marked elevation of liver enzymes (more than 5 times the upper limit of normal), marked hyperbilirubinaemia (more than 10 times the upper limit of normal), or obstructive jaundice and patients with other types of chronic liver diseases were excluded. As a part of the pretreatment assessment, the patients were subjected to an interview regarding their full history, a standard clinical examination (including body mass index), laboratory investigations (complete blood count, coagulation profile, and liver and kidney function tests), assessments of hepatitis B surface antigen, antinuclear antibody, and serum biomarkers of hepatic fibrosis (aspartate aminotransferase-to-platelet ratio index [15] and FIB-4 score [16]), abdominal ultrasound examination, liver stiffness measurement (LSM) using ultrasound transient elastography (FibroScan®, Echoscens, France), liver biopsy and histopathological examination.

### Liver stiffness measurement

Ultrasound transient elastography (FibroScan) with both ultrasound [3.5 MHz for the standard medium sized probe (M probe) and 2.5 MHz for the X-large probe (XL probe)] and low-frequency (50 Hz) elastic shear waves was used to measure liver stiffness in fasting patients (at least 4 h). Transient elastography was performed using FibroScan (Echoscens, Paris, France) before and in the same week as liver biopsy. XL probes have been primarily used in obese patients (body mass index >30 kg/m<sup>2</sup>). The device consists of a probe with an ultrasound transducer mounted on the axis of a vibrating piston. A piston is used to create a mechanical impulse, thus generating a low-frequency shear wave that propagates through the liver tissue. The ultrasound transducer, which is located at the tip of the probe, performs a series of ultrasound acquisitions to measure the speed of shear wave propagation. The liver stiffness, expressed in kPa, is calculated from this shear wave propagation speed. A higher shear wave velocity corresponds to greater liver stiffness, which represents a higher stage of fibrosis [4]. LSM was performed by an experienced hepatologist with more than 5 years of experience in performing the procedure who had completed more than 1000 examinations. The tip of the probe transducer was covered with coupling gel and placed on the skin between the ribs at the level of the right lobe of the liver. The operator, assisted by an ultrasonic time-motion image, located a portion of the liver that was at least 4-cm thick and free of large vascular structures. Measurements were taken using the

conventional standard M probe for patients with a body mass index below 30 kg/m<sup>2</sup> or the XL probe for patients with a body mass index greater than 30 kg/m<sup>2</sup>. During the acquisition, the subjects were lying on their backs with their right arm behind the head (maximal abduction) in a similar position to that used for liver biopsy. The operator obtained the measurements with the probe placed in the intercostal space. A minimum of 10 valid measurements were taken from the right lobe of the liver for each subject. The median values of the valid measurements were recorded as the LSM in kPa. LSM is considered unreliable if the interquartile range (IQR)/median LSM is >30% and the success rate is <60% [17].

### Biomarkers of liver fibrosis

The aspartate aminotransferase-to-platelet ratio index and FIB-4 score were calculated according to the following equations: APRI score was calculated using Wai's formula [15]:

$$(\text{AST}/\text{upper limit of normal})/\text{platelet count (expressed as platelets} \times 10^9/\text{L)} \times 100.$$

The FIB-4 score was calculated using Sterling's formula [16]:

$$\text{Age (years)} \times \text{AST (IU/L)}/\text{platelet count} (\times 10^9/\text{L}) \times \sqrt{\text{ALT (IU/L)}}.$$

### Liver biopsy and histopathological classification

Ultrasound-guided percutaneous liver biopsy was performed using 16-G semi-automated biopsy needles. Liver biopsy specimens (a minimum of 15 mm in length with at least four portal tracts) were fixed in 10% neutral formalin, processed, and then embedded in paraffin. Sections were stained with haematoxylin-eosin and Masson trichrome for the detection of fibrosis. Histopathological examinations were performed according to the METAVIR scoring system, with different stages for fibrosis (F0–F4) and grades of necroinflammatory activity (A0–A3) [18]. Histopathological examinations of liver biopsy specimens were performed by two independent expert pathologists familiar with liver tissue examination, and only concordant results were included in this study. The patients were further divided into three groups according to the stage of hepatic fibrosis: (i) significant hepatic fibrosis  $\geq$  F2; (ii) advanced hepatic fibrosis > F3, and (iii) cirrhosis (F4).

### Statistical analysis

The data were analysed using SPSS v21.0 for Windows. Categorical variables are summarized as the frequency counts and percentages. Continuous variables are summarized as the means and standard deviations.

In addition, the relationships between different variables were assessed through univariate analysis as follows. Categorical variables were assessed with the chi-squared test or the Fischer exact test where appropriate, and continuous variables were assessed using the independent samples *T* test or the Mann–Whitney *U* test according to the normality of their distribution. A receiver operating characteristic (ROC) curve was generated to determine the appropriate scores for predicting the stage of liver fibrosis that provide optimal sensitivity and specificity. Hypothesis testing was two-sided, and statistical significance was accepted at the 5% level. Significance was expressed as a *P* value.

## Results

Our study included 752 patients in two groups, group 1 (100 patients; training set) and group 2 (652 patients; validation set). Two hundred thirty-five (31.25%) patients were female, and 517

(68.75%) were male, with a mean age of 40.5 years. The mean body mass index was 28.2 kg/m<sup>2</sup>, the mean liver stiffness was 10.09, the mean APRI score was 0.73, and the mean FIB-4 score was 1.6. Other characteristics of both the training and validation sets are presented in Table 1.

LSM increased gradually with the stage of hepatic fibrosis in the training and validation sets. Other patient characteristics (age, AST, ALT, albumin, total bilirubin, international normalized ratio and platelet count) were also correlated with the stage of hepatic fibrosis (Tables 2 and 3). The mean LSM values and different patient characteristics at each stage of hepatic fibrosis (F0–F4) are presented in Table 2 (for the training set) and Table 3 (for the validation set).

Transient elastography was able to predict different stages of hepatic fibrosis and cirrhosis in both the training set and the validation set. In the training set, the best transient elastography cut-off values for significant hepatic fibrosis ( $\geq$ F2 METAVIR), advanced hepatic fibrosis ( $\geq$ F3 METAVIR) and cirrhosis (F4 METAVIR) were 7.1, 9 and 12.2 kPa, with sensitivities of 87%, 87.5% and 90.9%, specificities of 100%, 99.9% and 99.9% and areas under the receiver operator characteristic curve (AUROC) of 0.947, 0.976 and 0.958, respectively. The application of these cut-off values in the validation set showed sensitivities of 85.5%, 82.8% and 92%, specificities of 86%, 89.4% 99.01% and AUROC curve values of 0.895, 0.929, 0.956 for significant hepatic fibrosis, advanced hepatic fibrosis and cirrhosis, respectively.

Comparing the validated transient elastography cut-offs with APRI and FIB-4 values in the validation set showed the superiority of TE over APRI and FIB-4 for predicting significant hepatic fibrosis, severe hepatic fibrosis and cirrhosis. The sensitivity, specificity, AUROC curve, positive predictive values, negative predictive values and diagnostic accuracy of TE, APRI and FIB-4 in different stages of hepatic fibrosis are presented in Tables 4–6. The ROC curves for TE, APRI and FIB-4 in different stages of hepatic fibrosis for both the training and validation sets are presented in Figs. 1 and 2, respectively.

**Table 1**  
general characteristics of the studied groups.

Parameters	Training set	Validation set	p Value
Age Mean $\pm$ (SD)	40.29 (10.98)	41 (10.6)	.472
Gender n (%):			.691
Females	33 (33)	<b>202</b> (31)	
Males	67 (67)	450 (69)	
BMI Mean $\pm$ (SD)	28.20 (12.5)	27.89 (4.45)	.505
AST Mean $\pm$ (SD)	52.61 (31.62)	49.51 (33.59)	.387
ALT Mean $\pm$ (SD)	55.44 (33.12)	55.93 (42.59)	.912
Albumin Mean $\pm$ (SD)	4.19 (0.49)	3.96 (0.50)	<.001
T. Bil. Mean $\pm$ (SD)	0.81 (0.21)	0.90 (0.27)	<.001
PC% Mean $\pm$ (SD)	87 (21)	89.36 (9.24)	.019
PLT Mean $\pm$ (SD)	201.58 (59.02)	212.68 (69.59)	.313
GGT Mean $\pm$ (SD)	61.47 (54.10)	36.63 (39)	<.001
Stiffness Mean $\pm$ (SD)	10.09 (7.91)	9.87 (8.15)	.805
APRI Mean $\pm$ (SD)	0.73 (0.54)	0.70 (0.77)	.803
FIB-4 Mean $\pm$ (SD)	1.6 (1.05)	1.52 (1.19)	.570
<i>Biopsy (METAVIR)</i>			
<i>Fibrosis n (%):</i>			
F0	3 (3)	23 (3.5)	
F1	35 (35)	332 (51)	
F2	38 (38)	128 (19.6)	<b>.001</b>
F3	13 (13)	94 (14.4)	
F4	11 (11)	75 (11.5)	
<i>Activity n (%):</i>			
A0	0 (0)	1 (0.15)	
A1	71 (71)	590 (90.5)	
A2	24 (24)	55 (8.43)	<b>&lt;.001</b>
A3	5 (5)	6 (0.92)	

## Discussion

Assessments of hepatic fibrosis and cirrhosis enable clinicians to easily make therapeutic decisions and plan long-term screening for cirrhotic patients. Even with new HCV treatments using direct-acting antiviral agents, non-invasive methods for assessing liver fibrosis have important roles in monitoring fibrosis progression or fibrosis regression after a sustained virological response is achieved [19].

Transient elastography is considered a good alternative to liver biopsy for staging hepatic fibrosis and cirrhosis because it is accurate [20], reproducible [21], user-friendly [22] and potentially cost-effective [23]. Many studies have validated the use of transient elastography in different chronic liver diseases, especially CHC [24–29]. The most frequently used cut-off values range from 5.1–10.1 kPa for significant hepatic fibrosis ( $\geq$ F2 METAVIR), 8.0–15.4 kPa for advanced hepatic fibrosis ( $\geq$ F3 METAVIR) and 11.9–26.5 for cirrhosis (F4 METAVIR) [9]. All published transient elastography cut-off values were obtained from studies on populations other than Egyptian patients and may be affected by genotyping and the presence of other confounding factors (steatosis or old schistosomal infections). Therefore, establishing cut-offs that are suitable for Egyptian patients is extremely important as the use of locally validated cut-off values increases diagnostic accuracy in hepatic fibrosis.

Our study identified cut-off values of 7.1 kPa for significant hepatic fibrosis, 9 kPa for advanced hepatic fibrosis and 12.2 kPa for cirrhosis in Egyptians with CHC. These results are consistent with Castera et al. [30] and Cardoso et al. [31], who identified cut-off values of 7.1 kPa for significant hepatic fibrosis and 12.5 kPa for cirrhosis in CHC patients. Bonnard et al. (2014) studied the performance of FibroScan and other non-invasive measures in the Egyptian population. Although the same population was studied, different cut-off levels were obtained.

Bonnard et al. reported a BMI > 30 in 31% of their studied population, but the XL probe was not used, which may have led to difficulty in the measurement of liver stiffness and the possibility of overestimations of liver fibrosis in a high proportion of the patients. However, the APRI and FIB-4 cut-offs were nearly the same [14]. Although a significant difference was observed in both groups regarding serum albumin, total bilirubin and histological staging, these differences did not influence the diagnostic accuracy of the studied cut-offs. A comparison of the selected transient elastography cut-off values with those of frequently used serum fibrosis biomarkers (APRI and FIB-4) showed better sensitivity, specificity and AUROC curve values for transient elastography in the staging of hepatic fibrosis in our cohort, which is consistent with the recently published article by Houot et al. [32] that showed the superiority of transient elastography for the detection of cirrhosis in hepatitis C compared to serum fibrosis biomarkers and the recently published European guidelines regarding the use of non-invasive methods for the diagnosis of liver disease severity and prognosis [1].

Future validation of these cut-offs and the combination of serum fibrosis biomarkers with transient elastography to assess liver fibrosis can increase the diagnostic accuracy of both serum fibrosis biomarkers and transient elastography. Confounding factors (e.g., hepatic inflammation, hepatic congestion and fasting hours) that may interfere with transient elastography LSMs should be considered when interpreting the results.

Our results can be applied to other populations in the Middle East where genotype 4 CHC prevails. The limitations of this study include the absence of a comparison with patented serum fibrosis biomarkers (e.g., FibroTest, the enhanced liver fibrosis panel and FibroMeters) [33–35] and other radiological methods (e.g., acoustic

**Table 2**

Mean values of liver stiffness measurement, clinical and laboratory parameters in different fibrosis stages in the training set.

FIBROSIS (METAVIR)		STIFFNESS	AGE (year)	AST(U/L)	ALT(U/L)	ALBUMIN (g/L)	T.BIL (Umol/l)	INR	PLT (10 <sup>3</sup> /mm <sup>3</sup> )
F0 (n = 3)	Mean	4.70	38.67	49.67	42.67	44.00	12.54	1.13	215.67
	SD	0.62	12.05	21.01	34.96	7.93	5.50	0.058	16.56
F1 (n = 35)	Mean	5.65	34.57	44.66	46.14	41.97	12.95	1.08	204.54
	SD	0.810	9.28	27.85	26.44	4.60	3.45	0.11	55.10
F2 (n = 38)	Mean	8.04	40.13	46.50	53.39	42.63	13.81	1.11	208.16
	SD	1.91	11.26	27.02	31.01	5.26	3.24	0.12	54.30
F3 (n = 13)	Mean	16.50	49.38	71.54	78.23	41.62	16.048	1.128	205.46
	SD	10.34	7.94	38.35	46.77	3.52	4.55	0.14	94.07
F4 (n = 11)	Mean	25.18	48.73	77.45	68.64	38.82	14.92	1.127	161.00
	SD	8.79	5.06	34.53	28.62	5.23	2.66	0.13	22.14

**Table 3**

Mean values of liver stiffness measurement, clinical and laboratory parameters in different fibrosis stages in the validation set.

FIBROSIS METAVIR		AGE	ALT	AST	ALB	TBIL	PLT	PC	STIFFNESS
F0 (n = 23)	Mean	37.04	39.13	36.65	4.09	0.73	239	87.59	4.85
	SD	9.15	26.98	16.55	0.58	0.28	50.16	8.56	1.21
F1 (n = 332)	Mean	38.01	45.87	39.72	4.01	0.88	226.59	90.69	6.23
	SD	10.67	32.43	22.52	0.48	0.28	66.53	8.964	2.63
F2 (n = 128)	Mean	41.55	58.03	49.06	3.90	0.92	211.66	89.80	8.37
	SD	9.92	41.39	29.45	0.55	0.25	59.26	8.65	2.88
F3 (n = 94)	Mean	47.11	64.68	58.34	3.87	0.98	197.39	89.65	13.76
	SD	8.21	40.47	31.99	0.51	0.26	80.66	7.89	9.21
F4 (n = 75)	Mean	47.60	91.26	86.64	3.92	0.93	163.56	83.33	25.02
	SD	8.19	64.22	52.98	0.46	0.24	62.99	10.73	10.30

**Table 4**Cut off values of transient elastography, APRI and Fib-4 for detection of significant hepatic fibrosis ( $\geq$ F2).

	Cut off value	Sensitivity	Specificity	PPV	NPV	Overall accuracy	AUROC
Transient elastography(kPa)	7.1	85.5%	86%	82.2%	87.5%	84.9%	0.895
APRI	0.5	60%	65%	59.2%	66.1%	62.8%	0.704
FIB-4	1.05	74%	60%	61.1%	72.8%	66.3%	0.739

**Table 5**Cut off values of transient elastography, APRI and Fib-4 for detection of severe hepatic fibrosis ( $\geq$ F3).

	Cut off value	Sensitivity	Specificity	PPV	NPV	Overall accuracy	AUROC
Transient elastography(kPa)	9	82.8%	89.4%	73.1%	94.4%	87.9%	0.929
APRI	0.7	59.2%	79.4%	50.7%	84.6%	74.3%	0.753
FIB-4	1.45	71.6%	75.3%	51%	88.1%	74.4%	0.802

**Table 6**

Cut off values of transient elastography, APRI and Fib-4 for detection of Cirrhosis (F4).

	Cut off value	Sensitivity	Specificity	PPV	NPV	Overall accuracy	AUROC
Transient elastography(kPa)	12.2	92%	99%	57%	98.8%	91%	0.956
APRI	1	60%	89.5%	40.9%	94.4%	85.2%	0.808
FIB-4	2	70.7%	84%	36.8%	95.5%	82.3%	0.840

radiation force imaging and magnetic resonance elastography) [36] [37]. In conclusion, this study identified reasonable cut-off values for significant hepatic fibrosis, advanced hepatic fibrosis and cirrhosis that are feasible for current clinical use and future research in Egyptians with CHC.

#### Conflict of interest

All authors declare that they have no conflicts of interest related to this manuscript.

#### Ethical approval

All procedures performed within this study were in accordance with the ethical standards of the institutional review board of Cairo University and with the 1964 Declaration of Helsinki and its later amendments.

#### Informed consent

Informed consent was obtained from all individual participants included in the study.



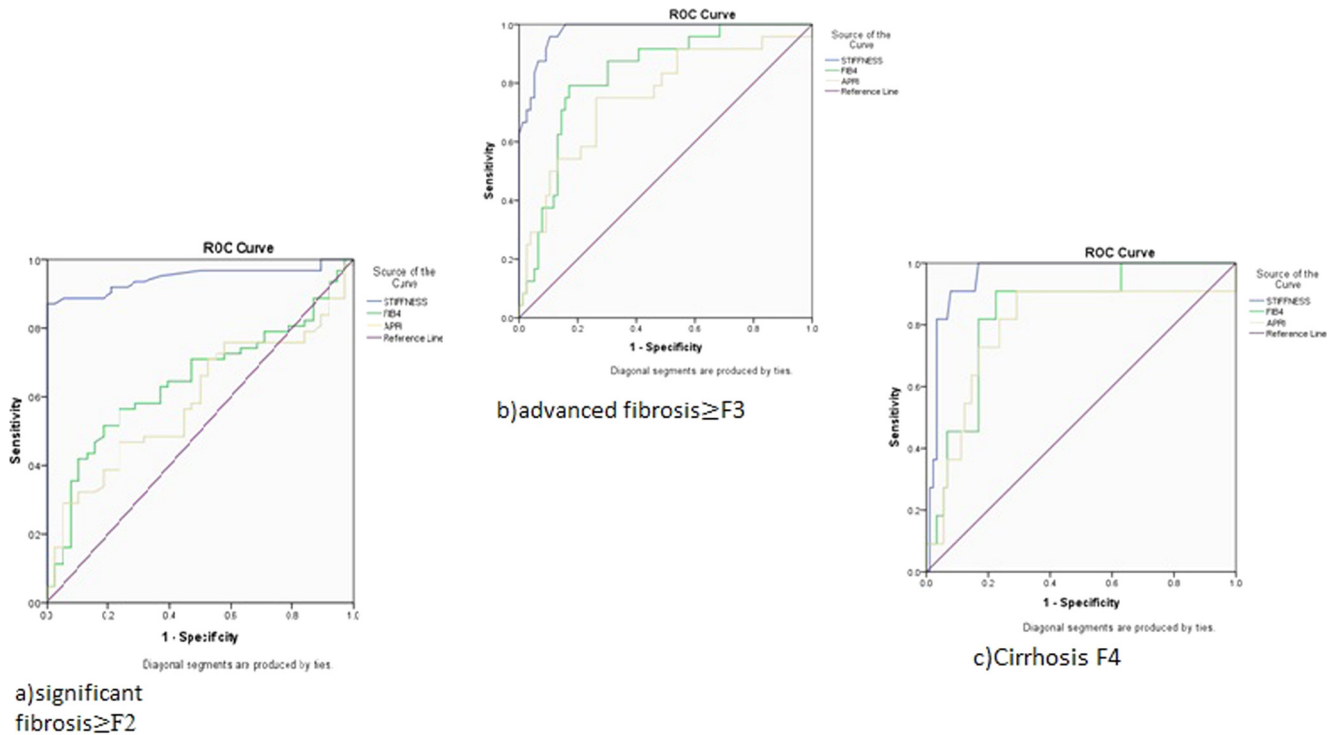


Fig. 1. ROC curves for FibroScan, APRI and FIB-4 for significant hepatic fibrosis (a), advanced hepatic fibrosis (b) and cirrhosis (c) in the training set.

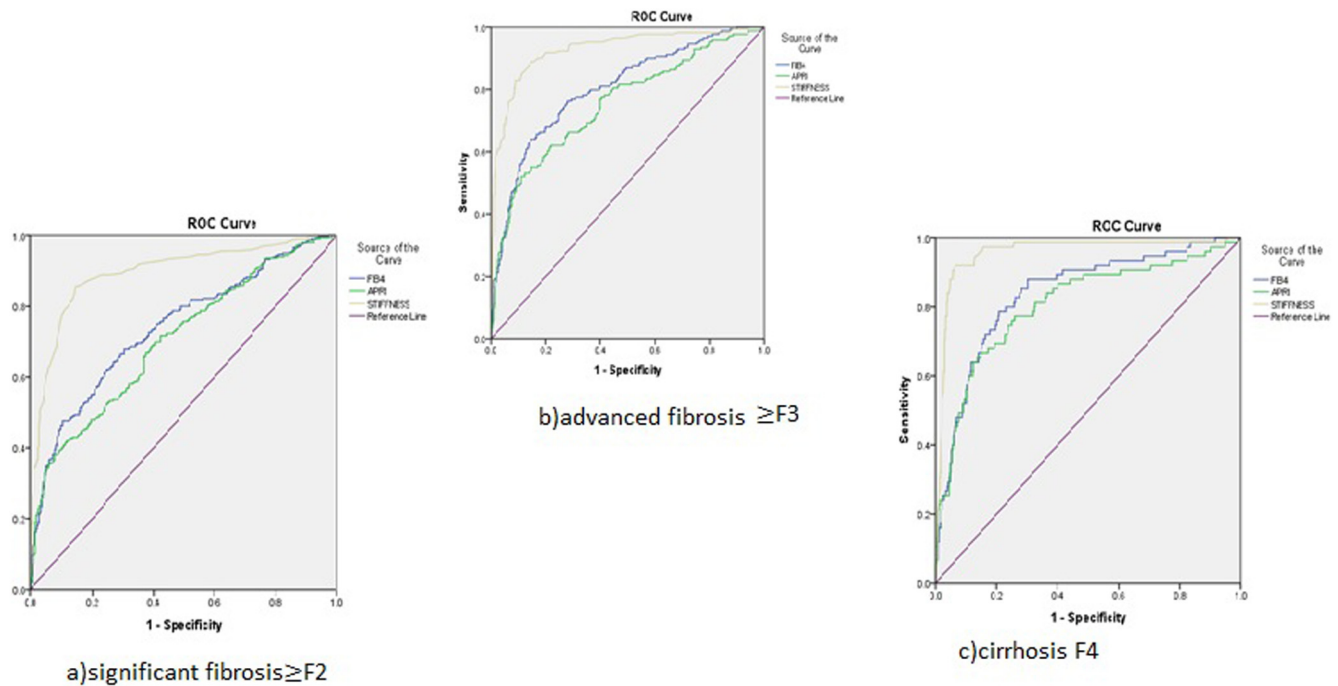


Fig. 2. ROC curves for FibroScan, APRI and FIB-4 for significant hepatic fibrosis (a), advanced hepatic fibrosis (b) and cirrhosis (c) in the validation set.

## Funding sources

This research did not receive any specific grant from funding agencies in the public, commercial, or not-for-profit sectors.

## References

- [1] EASL-ALEH Clinical Practice Guidelines. Non-invasive tests for evaluation of liver disease severity and prognosis. *J Hepatol* 2015;63(1):237–64.
- [2] Yosry A, Fouad R, Alem SA, Elsharkawy A, El-Sayed M, Asem N, et al. FibroScan, APRI, FIB4, and GUCI: role in prediction of fibrosis and response to therapy in Egyptian patients with HCV infection. *Arab J Gastroenterol* 2016 Jun;17(2):78–83. Epub 2016 Jun 25.

- [3] Sandrin L, Fourquet B, Hasquenoph JM, Yon S, Fournier C, Mal F, et al. Transient elastography: a new noninvasive method for assessment of hepatic fibrosis. *Ultrasound Med Biol* 2003 Dec;29(12):1705–13.
- [4] Lupsor-Platon M, Badea R. Noninvasive assessment of alcoholic liver disease using unidimensional transient elastography (FibroScan®). *World J Gastroenterol* 2015;21(42):11914–23.
- [5] Koh CI, Turner T, Zhao X, Minniti CP, Feld JJ, Simpson J, et al., Liver Stiffness Increases Acutely During Sickle Cell Vaso-Occlusive Crisis. *American journal of hematology*, 2013. 88(11): p. DOI: 10.1002/ajh.23532.
- [6] Friedrich-Rust M, Ong MF, Martens S, Sarrazin C, Bojunga J, Zeuzem S, et al. Performance of transient elastography for the staging of liver fibrosis: a meta-analysis. *Gastroenterology* 2008;134(4). p. 960–974.e8.
- [7] Stebbing J, Farouk L, Panos G, Anderson M, Jiao LR, Mandalia S, et al. A meta-analysis of transient elastography for the detection of hepatic fibrosis. *J Clin Gastroenterol* 2010;44(3):214–9.
- [8] Tsochatzis EA, Gurusamy KS, Ntaoula S, Cholongitas E, Davidson BR, Burroughs AK. Elastography for the diagnosis of severity of fibrosis in chronic liver disease: a meta-analysis of diagnostic accuracy. *J Hepatol* 2011;54(4):650–9.
- [9] Wong GL-H. Update of liver fibrosis and steatosis with transient elastography (FibroScan). *Gastroenterology Report*, 2013.
- [10] Alborai MA, Afifi ME, Elghamry FG, Shalaby HA, Elshennawy GE, Abdelaziz AA, et al. Ely-score predicts severe hepatic fibrosis and cirrhosis in Egyptians with chronic liver diseases: a pilot study. *Hepat Mon* 2013;13(6):e10810.
- [11] Alborai M, Khairy M, Elsharkawy A, Elsharkawy M, Asem N, Abo El-Seoud AR, et al. Ely-score as a noninvasive score for the assessment of hepatic fibrosis in chronic hepatitis C: a preliminary approach. *Saudi J Gastroenterol* 2014;20(3):170–4.
- [12] Alborai M, Khairy M, Elsharkawy M, Asem N, Elsharkawy A, Esmat G. Value of Ely-Score in diagnosis of significant, advanced hepatic fibrosis and cirrhosis compared to aspartate aminotransferase-to-platelet ratio index, FIB-4 and Forns' index in chronic hepatitis C virus. *Hepatol Res* 2015 May;45(5):560–70.
- [13] Bonnard P, Elsharkawy A, Zalata K, Delarocque-Astagneau E, Biard L, Le Foulher L, et al. Comparison of liver biopsy and noninvasive techniques for liver fibrosis assessment in patients infected with HCV-genotype 4 in Egypt. *J Viral Hepat* 2015 Mar;22(3):245–53. Epub 2014 Jul 30.
- [14] Wai CT, Greenon JK, Fontana RJ, Kalbfleisch JD, Marrero JA, Conjeevaram HS, et al. A simple noninvasive index can predict both significant fibrosis and cirrhosis in patients with chronic hepatitis C. *Hepatology* 2003;38(2):518–26.
- [15] Sterling RK, Lissen E, Clumeck N, Sola R, Correa MC, Montaner J, et al. Development of a simple noninvasive index to predict significant fibrosis in patients with HIV/HCV coinfection. *Hepatology* 2006;43(6):1317–25.
- [16] Boursier J, Zarski JP, de Ledinghen V, Rousselet MC, Sturm N, Le Bail B, et al. Determination of reliability criteria for liver stiffness evaluation by transient elastography. *Hepatology* 2013;57(3):1182–91.
- [17] Bedossa P, Poynard T. An algorithm for the grading of activity in chronic hepatitis C. The METAVIR Cooperative Study Group. *Hepatology* 1996;24(2):289–93.
- [18] Elsharkawy A, Abdel Alem S, Fouad R, El Raziky M, El Akel W, Abdo M, et al. Changes in Liver stiffness measurements and Fibrosis scores following Sofosbuvir based treatment regimens without Interferon. *J Gastroenterol Hepatol*. 2017 Feb 8. [Epub ahead of print].
- [19] Wong GL-H. Transient elastography: Kill two birds with one stone? *World J Hepatol* 2013;5(5):264–74.
- [20] Behairy Bel-S, Sira MM, Zalata KR, Salama el-SE, Abd-Allah MA, et al. Transient elastography compared to liver biopsy and morphometry for predicting fibrosis in pediatric chronic liver disease: does etiology matter? *World J Gastroenterol* 2016;22(16):4238–49.
- [21] Cobbold JFL, Morin S, Taylor-Robinson SD. Transient elastography for the assessment of chronic liver disease: ready for the clinic? *World J Gastroenterol*: WJG 2007;13(36):4791–7.
- [22] Thavorn K, Coyle D. Transient elastography and controlled attenuation parameter for diagnosing liver fibrosis and steatosis in Ontario: an economic analysis. *Ontario Health Technol Assess Series* 2015;15(19):1–58.
- [23] Ziol M, Handra-Luca A, Kettaneh A, Christidis C, Mal F, Kazemi F, et al. Noninvasive assessment of liver fibrosis by measurement of stiffness in patients with chronic hepatitis C. *Hepatology* 2005;41(1):48–54.
- [24] de Ledinghen V, Barreiro P, Foucher J, Labarga P, Castéra L, Vispo ME, et al. Liver fibrosis on account of chronic hepatitis C is more severe in HIV-positive than HIV-negative patients despite antiretroviral therapy. *J Viral Hepat* 2008;15(6):427–33.
- [25] Vergara S, Macías J, Rivero A, Gutiérrez-Valencia A, González-Serrano M, Merino D, et al. The use of transient elastometry for assessing liver fibrosis in patients with HIV and hepatitis C virus coinfection. *Clin Infect Dis* 2007;45(8):969–74.
- [26] Marcellin P, Ziol M, Bedossa P, Douvin C, Poupon R, de Ledinghen V, et al. Non-invasive assessment of liver fibrosis by stiffness measurement in patients with chronic hepatitis B. *Liver Int* 2009;29(2):242–7.
- [27] Wong VW, Vergniol J, Wong GL, Foucher J, Chan HL, Le Bail B, et al. Diagnosis of fibrosis and cirrhosis using liver stiffness measurement in nonalcoholic fatty liver disease. *Hepatology* 2010;51(2):454–62.
- [28] Nahon P, Kettaneh A, Tengher-Barna I, Ziol M, de Ledinghen V, Douvin C, et al. Assessment of liver fibrosis using transient elastography in patients with alcoholic liver disease. *J Hepatol* 2008;49(6):1062–8.
- [29] Castéra L, Vergniol J, Foucher J, Le Bail B, Chanteloup E, Haaser M, et al. Prospective comparison of transient elastography, Fibrotest, APRI, and liver biopsy for the assessment of fibrosis in chronic hepatitis C. *Gastroenterology* 2005;128(2):343–50.
- [30] Cardoso AC, Carvalho-Filho RJ, Stern C, Dipumpo A, Giuily N, Ripault MP, et al. Direct comparison of diagnostic performance of transient elastography in patients with chronic hepatitis B and chronic hepatitis C. *Liver Int* 2012;32(4):612–21.
- [31] Houot M, Ngo Y, Munteanu M, Marque S, Poynard T, et al. Systematic review with meta-analysis: direct comparisons of biomarkers for the diagnosis of fibrosis in chronic hepatitis C and B. *Aliment Pharmacol Ther* 2016;43(1):16–29.
- [32] Poynard T, Morra R, Halfon P, Castera L, Ratziv V, Imbert-Bismut F, et al. Meta-analyses of FibroTest diagnostic value in chronic liver disease. *BMC Gastroenterol* 2007;7:40.
- [33] Fernandes FF, Ferraz ML, Andrade LE, Dellavence A, Terra C, Pereira G, et al. Enhanced liver fibrosis panel as a predictor of liver fibrosis in chronic hepatitis C patients. *J Clin Gastroenterol* 2015;49(3):235–41.
- [34] Calès P, Boursier J, Oberti F, Hubert I, Gallois Y, Rousselet MC, et al. FibroMeters: a family of blood tests for liver fibrosis. *Gastroenterol Clin Biol* 2008;32(6 Suppl 1):40–51.
- [35] Sporea I, Bota S, Peck-Radosavljevic M, Sirlu R, Tanaka H, Iijima H, et al. Acoustic radiation force impulse elastography for fibrosis evaluation in patients with chronic hepatitis C: an international multicenter study. *Eur J Radiol* 2012;81(12):4112–8.
- [36] Ichikawa S, Motosugi U, Ichikawa T, Sano K, Morisaka H, Enomoto N, et al. Magnetic resonance elastography for staging liver fibrosis in chronic hepatitis C. *Magn Reson Med* 2012;11(4):291–7.